

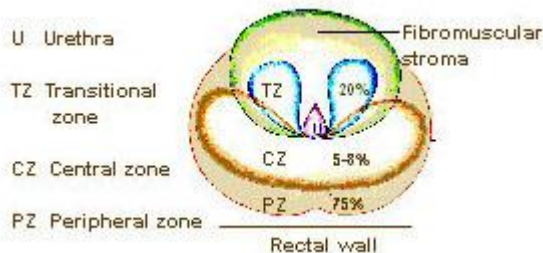
Following from the National Cancer Institute (NCI) Surveillance, Epidemiology, and End Results (SEER) Training Modules:

### Anatomy of the Prostate

- The prostate is a gland of the male reproductive system. It is located in front of the rectum and just below the bladder, the organ that stores urine.
- The main purpose of the prostate is to produce fluid for semen, which transports sperm during the male orgasm.
- The prostate consists of a base, an apex, an anterior, a posterior and two lateral surfaces.
- The prostate is divided into several lobes: the anterior lobe, the median lobe, the lateral lobes (left and right lobes), and the posterior lobe.
- The prostate is also divided, by scientists, into different zones according to their function: the central zone (CZ), peripheral zone (PZ), and transitional zone (TZ).

<http://training.seer.cancer.gov/prostate/anatomy/review.html>

- 
- **Zones of the Prostate**
- Scientists divide the prostate up into different zones according to their function. The zones are Central (CZ), Peripheral (PZ) and Transitional (TZ).



- 
- Prostate cancer can begin and spread from any of these zones.

<http://training.seer.cancer.gov/prostate/anatomy/zones.html>

### Lobes of the Prostate

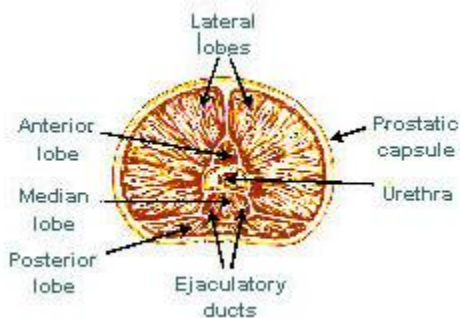
The prostate is divided into several lobes.

## Anterior Lobe

The anterior lobe is used to describe the anterior portion of the gland lying in front of the urethra. It is devoid of glandular tissue being formed completely of fibromuscular tissue.

## Median Lobe

The median lobe is a cone-shaped portion of the gland situated between the two ejaculatory ducts and the urethra.



## Lateral Lobes

The lateral lobes (right and left lobes) form the main mass of the gland and are continuous posteriorly. They are separated by the prostatic urethra.

## Posterior Lobe

The posterior lobe is used by some to describe the postero-medial part of the lateral lobes that can be palpated through the rectum during digital rectal exam (DRE).

<http://training.seer.cancer.gov/prostate/anatomy/lobes.html>